



THE AMELIORATIVE EFFECT OF MORIN AGAINST METHOTREXATE – INDUCED HEPATOTOXICITY AND SOME PHYSIOLOGICAL AND BIOCHEMICAL IN MALE RATS

Husam Atiya Khadhim¹ and Hussein khudhair Al-mayali²

Department of Biology, College of Education, University of Al-Qadisiyah, Iraq.

Abstract

Morin possesses therapeutic properties through, which a course as an antioxidant and a sweep of free radicals, anti-inflammatory, anti-bacterial, heart tonic and anti-tumor. The purpose of this study is to investigate the role of the Morin compound against the toxic effects of Methotrexate in white male rats.

Sixty males of white rats aged (10-12) were used in this experiment. The rats were divided randomly into six groups (10 rats per group). The first group was of a negative control (C) and was pumped with distilled water only for four weeks. The second group was of positive control (T1) with Methotrexate by (0.250) mg / kg B.W for four weeks, The third (T2) was given the Morin compound only with concentration (25) mg / kg B.W. for four weeks; the fourth (T3) was orally injected with the drug for two weeks. Then the drug was treated with Morin (25) mg / kg B.W for two more weeks. The fifth (T4) was treated with For Morin for two weeks and then Methotrexate was given in the last two weeks. The sixth (T5) was given both drugs Methotrexate and Morin at the same time and simultaneously for four weeks. The rats were sacrificed and blood was taken from them for the sake of observing the effects of the studied characteristics.

The results of the statistical analysis show a significant increase in the level of the enzymes of the liver AST, ALT, ALP. also significant increase in MDA and significant decrease in GSH, SOD and significant decrease in the level NF- κ B, IL-6, HP of the given drug group (T1) as compared to negative control and other aggregates. While the groups treated by Morin were clearly improved and decreased in level AST, ALT, ALP also in the MDA level with high levels of antioxidants GSH, SOD and immunoglobulin HP, IL-6, NF- κ B especially in the two groups (T2, T5). It can be concluded that Morin with a dose of 25 mg / kg has a protective and therapeutic role in reducing the toxicity of MTX in male rats.

Key words : Morin, Methotrexate, Hepatotoxicity.

Introduction

Methotrexate (MTX) is a chemotherapy and immunosuppressant, which is used to treat cancers such as breast cancer, leukemia, lung cancer, and autoimmune diseases such as psoriasis, Crohn's disease, rheumatoid arthritis (Balk, 2011). It is a folic acid antagonist that acts on the metabolism of this acid because of the similarity in the molecular structure between folic acid and MTX (Fitzakerley, 2011). MTX biotransformation in the liver produce active metabolites that promote hepatotoxicity due to the increase of the oxidative stress (Jahovic *et al.*, 2003). This also other common effects such as hypoproteinemia, immunosuppression, pulmonary fibrosis

and kidney failure (Sneider, 2005). Methotrexate is also induced to increase the number of fat-storing cells that could be transformed into myofibroblast responsible for collagen secretion, which leads to liver cirrhosis (Ohbayashi *et al.*, 2010). Some scientific evidence and studies suggest that the combination of chemotherapy and antioxidants in specific doses can help in improving drug effectiveness or reducing the severity of side effects (Rabovsky *et al.*, 2010) by stimulating antioxidants, improving immunity and motivating DNA repair mechanisms by the role of protective enzymes.

Morin C₁₅H₁₀O₇ (pentahydroxyflavone-5,7,'3,4,'2) is a yellowish pigment and potent flavonoid abundantly,

present in the plants of the Moraceae family (Yoa *et al.*, 2017). Flavonoids are the main components of the human diet, Morin has therapeutic properties in which it acts as an antioxidant and anti-cancer, especially for liver cancer by promoting apoptosis (Sivaramakrishnan and Devaraj, 2010). Morin also shows regular preventive measures and reduces the negative side effects of many drugs without interfering with their functions, It is a promising natural medicine because of beneficial effects on many human diseases (Caselli *et al.*, 2016). The present study is designed to evaluate the protective effect of Morin against MTX-induced hepatotoxicity in rats.

Materials and Methods

Experimental animals

In this experiment, Sixty adult male Wister rats were used, about four month old, with average weight about (160.5±13gm) obtained from animal house in college of veterinary Medicine at University of AL-Qadisiyah. The animals housed in well ventilated wire-plastic cages with dimensions 40×60 cm and reared under controlled conditions about 12 hour light and 12 hour dark at 22°C. The animals were allowed to acclimatize for 10 days before experimentation.

Drugs and chemicals

MTX was purchased from the local pharmacy and factory by the Turkish company PFIZER and was used at a concentration of 0.250 mg/kg B.W. for 28 days. Morin was purchased from Sigma Chemical Company, St. Louis, MO, USA and was given orally by intra gastric tube (gavage) at a dose of 25 mg/kg as described.

Experimental design

Sixty adult male Wister rats were divided randomly into six equal groups (10 animals for each group) and treated for 28 consecutive days as following:

1. Control group (C) was given 1 ml distilled water orally.
2. The first treated group (T1) was given MTX orally in a dose of 0.250 mg/kg B.W once daily dissolved in 1 ml distilled water for 28 days (Patel *et al.*, 2014).
3. The second treated group (T2) was given Morin orally in a dose of 25 mg/kg B.W once daily dissolved in 1 ml distilled water for 28 days (Galvez *et al.*, 2001).
4. The third treated group (T3) was given MTX orally (0.250mg/kg/B.W) for 14 days then given orally Morin 25 mg/kg B. W/day for 14 days.
5. The fourth treated group (T4) was given Morin orally (10 mg/kg B.W/day) for 14 days then given orally MTX (0.250 mg/kg B.W/day) for 14 days.

6. The sixth treated group (T5) was given both drugs MTX and Morin at the same time and simultaneously for 28 days.

Animals sacrificing and collection of blood samples

Twenty four hours after last administration all animals were anaesthised by mixing of Ketamine and Xylocaine (0.3ml, 0.1m), respectively intraperitoneal, to sacrificed then blood samples were collected from the heart to obtain the serum of animals. Blood was collected from each animal directly from the heart by using 5 ml disposable syringe, then putting in gel and clot activator tube and left at room temperature until clotted, then it were centrifuged at 3000 rpm for 15 minutes, the serum was aspirated from the tube and stored at -20°C until used for analysis.

Biochemical estimation

Measuring the concentration of liver enzymes

Determination of Serum Alanine Amino Transferase (ALT), Determination of Serum Aspartate Amino Transferase (AST), Determination of Serum Alkaline Phosphatase (ALP):

These enzymes were measured by placing the serum directly in a dry chemical analyzer ARKRAY Spotchem EZ SP-4430 with a special tube with a detector tape for each type of liver enzymes above. After about five minutes, the results of the test were recorded for each eye.

Assessment of MDA concentration

By using the Thiobarbituric acid (TBA) method of Buege and Aust for determination of serum MDA, in which MDA reacts with TBA to give a pink color that is read at 532 nm. (Guidet and Shah, 1989).

Determination of glutathione (GSH) concentration

The method is based on the use of the Ellman's reagent detector as it reacts rapidly with GSH and is reduced by the sulfate group (SH group) of the glutathione, forming a color product whose absorption is read at 412 nm. (Sedlak and Lindsay, 1968).

Determination of superoxide dismutase (SOD) concentration

The effect of superoxide dismutase in the serum was measured using the chemo-optical modulation method Nitroblue tetrazolium (NBT). Using sodium cyanide as an inhibitor of peroxidase whose absorption is read at 560 nm (Durak *et al.*, 1996).

Measure the serum level of (HP, IL-6 and NF-κB)

The concentration of HP, IL-6 and NF-κB in the serum was estimated using the Elisa device and the

equipment manufactured by CUSABIO, Chain.

Histopathological studies

The liver and spleen were excised and fixed in 10% formalin and stained with haematoxylin and eosin and then observed under microscope for histopathological changes.

Statistical analysis

A computerized program, the statistical package for social sciences (SPSS) was used to analyze data. The data were expressed as means \pm standard errors (SE). Differences between group means were estimated using a one-way analysis of variance (ANOVA) with least significant difference LSD was detected to compare between groups and Results were considered statistically significant at $P < 0.05$ (Joda, 2008).

Results

There was a significant increase in the activity of AST, ALT and ALP in animal groups treated with MTX as compared to control groups. However, supplementation of MTX intoxicated rats with Morin (T3, T4) ameliorated the antitubercular drugs adverse effects as evidenced by a significant decrease in ALT, AST and ALP activity. There were no significant differences between totals (T2, T5) compared to negative control as shown in table 1.

Table 2 showed that T1 group appeared a significant increase ($P < 0.05$) in concentration of MDA, when compared with other groups, while there was a significant decrease in concentration of MDA in T2 group. Also, there was a significant decrease in concentration of MDA in T3 group and T4 group respectively as compared with T1 group. Likewise there were no significant differences ($P \geq 0.05$) between T2, T5 and C group.

Table 2 demonstrated there was a significant increase ($P < 0.05$) in GSH, SOD concentration in T2 group as compared with other groups, while there was a significant decrease in GSH, SOD concentration in T1 group as compared with other groups and there was a significant difference in GSH, SOD concentration between T3 and T4 groups represented by the increase of GSH, SOD concentration in T4 when compared with T3 group. And there were no significant differences between T5 and C group.

The results of the statistical analysis of the current study showed a significant decrease ($P < 0.05$) in the level (HP-IL-6 – NF-kB) for male rats treated with MTX (T1) at a concentration of 0.250 mg/kg compared with the negative control group (C) as well as with the

other groups (T2, T3, T4, T5). There was also a significant decrease ($P < 0.05$) in the T4 group which was treated with Morin for 14 days at a concentration of 25 mg/kg before MTX as compared to other Morin groups (T2, T3, T5). And there were no significant differences between (T2, T3, T5) and C group (table 3).

The histological examination of the liver sections showed that MTX administration caused major histological changes in comparison with the control such as inflammatory cell infiltrations, vascular congestion, sinusoidal dilatation and granular degeneration of hepatocytes, Hyperplasia and congestion of the bile duct are noted (fig. 1). Treatment with Morin showed a typical structure in liver tissue (fig. 2). While in MTX+Morin group, the histological changes were less severe than those in the MTX treated group; these changes were granular degeneration of hepatocytes and sinusoidal dilatation at low levels and simple propagation in Kupffer cells (fig. 3).

Histological examination of the spleen was shown in the group (T1) treatment with MTX clear exhaustion of white pulp with multiplication of red pulp as well as lymphocyte degeneration in the white pulp. With a presence Multinucleated gaint cells appear within the lymphatic tissue (fig. 4). Treatment with Morin showed a typical structure in spleen tissue (fig. 5). While in MTX with Morin groups, showed a clear improvement represented by the presence of a large white pulp and spread with the presence of arterioles surrounded by a red pulp as well as slight degeneration in lymphocytes (fig. 6).

Discussion

Level of liver enzymes (ATS, ALT, ALP)

The results agreed upon match with what Jwied (2009) reached at after injecting rats with MTX. Al-Fatlawi and Al-Shammari (2017) also referred to the increase of ALT and AST in rats after being given MTX. These enzymes often increase due to the hepatic degeneration, which appears two weeks to two months after the use of chemotherapy including MTX (Robinson *et al.*, 2013). Due to oxidative damage to the liver resulting from the toxic effects of MTX, the substances that are toxic in the liver cells lead to increased permeability of the membranes of those cells and thus a significant leakage of these enzymes into the serum and its reduction in the liver (Bonnetfoi *et al.*, 1989). Toxic substances and drugs also increase the effectiveness of the lysosomes, which causes damage to all organelles within the cell leading to the death of hepatic cells a significant increase

in liver enzymes appears in the serum (Rawat *et al.*, 1997). The ALP enzyme, another indicator of liver damage is elevated due to blockage in the bile ducts the bile flow into or out of the liver leads to a rise ALP in serum (Nair *et al.*, 1998). As for the groups that have been treated Morin with MTX (T3, T4, T5) there has been a marked improvement in the level of liver enzymes compared to positive control (T1), but treatment in group (T5) was more efficient in maintaining liver enzymes and no significant differences were observed with negative control group, the reason is that Morin is a powerful antioxidant that works to protect hepatic cells from damage to free radicals by stimulating cellular antioxidant enzymes (Kok *et al.*, 2000). Morin also regulates the expression of metabolic enzyme activities including cytochrome - P450 (Hodek *et al.*, 2002). The same results are reached Subash and Subramanian (2012), agreed with study of both Zayni and Abbas (2012) the efficacy of ALT and AST in rats was improved when administered Morin at 30 mg/kg. This proves that Morin has protective properties against liver toxicity caused by MTX.

The level of antioxidants and oxidants (SOD, GSH, MDA)

These results were consistent with both Sail *et al.* (2013) and Tousson *et al.* (2014), when male rabbits and male rats were treated respectively with MTX and caused a significant increase in MDA and also coincided with the results of Zheng *et al.* (2014) of the presence of a high level of MDA with a decrease in the level of both GSH, SOD when rats were treated with Cisplatin. The lipid peroxidation is an indicator of harmful oxidative stress in tissues that causes damage to cellular fat content free compounds such as malondialdehyde, the final product of lipid peroxidate are released (Berryman *et al.*, 2005). This is associated with a decrease in the effectiveness of antioxidant enzymes GSH, SOD because they are antioxidant enzymes that contribute to the prevention of oxidation induced by the drug by direct removal of free radicals and that these enzymes are depleted because they represent a defensive line against the toxicity of the reactive oxygen species generated by the effect of MTX, which may be reduced due to increased demolition or lack of manufacturing (Hudson, 1999). As a result of deficiency in the raw materials necessary to build these enzymes during oxidative stress (Weiji *et al.*, 2004). For example, MTX causes enzyme inhibition glucose-6-phosphate dehydrogenase, which contributes to the reduction of the chemical compound NADPH, which is a factor in important biological reactions thus, the reduction of NADPH inhibits the GSH

cycle (Rouse *et al.*, 1995). In contrast, the Morin showed the ability to increase the GSH NADPH structure by regulating the activation of the nuclear factor 2(Nrf2) (Rizvi *et al.*, 2015). So that Nrf2 increases the synthesis of Glutathione by stimulating GCLC and GCLM (Glutamate Cysteine Ligase) to regenerate gathering GSH in the liver. She agreed with the results of Sreedharan *et al.* (2009), when treating male rats with Morin at a concentration of 50 mg/kg of low MDA and high levels of enzymatic and non-enzymatic antioxidants GPx, GSH, CAT, SOD. The same results were reported by both Heeba and Mahmoud (2014) from low MDA concentration and elevated GSH to normal levels when rats were treated with 30 mg/kg of Morin. Morin protects the mitochondrial membranes from damage to free radicals thereby ensuring continuous energy production and the effectiveness of oxidative enzymes (Lee *et al.*, 2016). Morin was also effective in balancing the levels of these enzymes in liver tissue of mice (Singh *et al.*, 2015).

Level of immunological standards (NF- κ B, IL-6, HP)

MTX is an immunosuppressant. Chemotherapy reduces the level of albumin in the serum causing a decrease in total protein, including immune proteins (Parrish *et al.*, 2006). In line with Darwish *et al.* (2013) study that the use of MTX for three weeks in rats inhibits NF- κ B, Chiad and his Cohort (2015) reported that treating patients with MTX resulted in a decrease in pro-inflammatory cytokines such as (IL-1 β , IL-6, TNF- α). MTX was found to have an inhibitory effect on infiltration macrophages, which secrete high levels of these cytokines, Gerards *et al.* (2003) reported that MTX is an effective inhibitor for the production of cytokines, including IL-6 because of the drug caused by the metabolism of folate they observed that when folic acid was added, it reversed the inhibitory effects of methotrexate on the production of cytokines. As for the reduction of (HP) haptoglobin found Cronstein *et al.* (1993) the treatment of mice for four weeks with MTX has prevented the proliferation of immunoglobulin cells for peripheral blood cells by reducing the synthesis of polyamine. The increase in HP is also associated with activation of transcription of genes by pro-inflammatory cytokines such as IL-6 (Baumann *et al.*, 1989). Morin has a role in inhibiting this activity by deactivating NF- κ B and promoting apoptosis (Manna *et al.*, 2007). Bachawal *et al.* (2017) reported the treatment of oral Morin rats at 50 and 100 mg/kg it's inhibited NF- κ B by reducing (ROS) and increasing antioxidant activity. The Morin activates the enzyme kinase (IKK) it works on

Table 1 : Effect of Morin treatment on the level of some liver enzymes (ALP-ALT-AST) in male rats treated with MTX .

Groups Parameters	C	T1	T2	T3	T4	T5	L.S.D
ASTIU / L	47.1 ± 2.04D	61.9 ± 3.06A	45.1 ± 2.58D	52.73 ± 1.50C	59.03 ± 2.13 B	50.23 ± 2.06D	6.512
ALTIU / L	20.07 ± 2.05C	35.63 ± 2.53A	22.80 ± 1.05C	28.21 ± 1.51B	27.55 ± 1.51B	21.22 ± 1.05C	8.291
ALPIU / L	121.04 ± 2.55D	209.5 ± 2.71A	128.11 ± 1.05D	137.77 ± 1.55C	175.83 ± 2.04B	133.21 ± 2.0DC	7.199

Numbers = mean ± Standard Error (S.E). Different litters = Significant Differences (p<0.05).

C= Control group, drenched orally with distilled water for (28) days.

T1= Drenched orally with MTX (0.250 mg /kg B.W/day) for (28) days.

T2= Drenched orally with Morin (25mg/kg B.W/day) for (28) days.

T3= Drenched orally with MTX (0.250 mg/kg/B.W)for (14) days then with Morin (25 mg/kg/B.W) for (14) days.

T4= Drenched orally with Morin (25 mg/kg/B.W) for (14) days then with MTX (0.250 mg/kg/B.W) for (14) days. T5 = Drenched orally with MTX and Morin at the same time and simultaneously for 28 days.

Table 2 : Effect of Morin treatmentat (MDA – GSH-SOD) level in male rats treated with MTX.

Groups Parameters	C	T1	T2	T3	T4	T5	L.S.D
MDA (µ mol/L)	1.69 ± 0.04C	3.38 ± 0.02 A	1.65 ± 0.02C	1.56 ± 0.01D	1.85 ± 0.02B	1.79 ± 0.02C	0.152
GSH (µ mol/L)	2.01 ± 0.33B	1.47 ± 0.03F	2.88 ± 0.01A	1.55 ± 0.02D	1.62 ± 0.02C	1.87 ± 0.03BC	0.291
SOD(U 8 mL)	2.82 ± 0.04B	1.69 ± 0.03F	3.63 ± 0.02 A	2.04 ± 0.03D	2.25 ± 0.02C	2.61 ± 0.05BC	0.395

Numbers = mean ± Standard Error (S.E). Different litters = Significant Differences (p<0.05).

C= Control group, drenched orally with distilled water for (28) days.

T1= Drenched orally with MTX (0.250 mg /kg B.W/day) for (28) days.

T2= Drenched orally with Morin (25mg/kg B.W/day) for (28) days.

T3= Drenched orally with MTX (0.250 mg/kg/B.W) for (14) days then with Morin (25 mg/kg/B.W) for (14) days.

T4= Drenched orally with Morin (25 mg/kg/B.W) for (14) days then with MTX (0.250 mg/kg/B.W) for (14) days. T5 = Drenched orally with MTX and Morin at the same time and simultaneously for 28 days.

Table 3 : Effect of Morin treatmentat (HP –IL-6–NF-κB) level in male rats treated with MTX.

Groups Parameters	C	T1	T2	T3	T4	T5	L.S.D
HP(ng/ml)	3.93 ± 0.04A	2.17 ± 0.01D	4.07 ± 0.01A	3.58 ± 0.02AB	2.23 ± 0.04C	3.70 ± 0.04A	1.151
IL-6(pg/ml)	22.74 ± 0.13A	15.73 ± 0.14D	22.98 ± 0.3A	19.15 ± 0.3AB	17.53 ± 0.2C	21.70 ± 0.25A	2.932
NF-κB (pg/ml)	44.09 ± 0.47A	24.33 ± 0.3D	46.7 ± 0.14A	38.46 ± 0.3AB	29.49 ± 0.16C	40.18 ± 0.2A	3.290

Numbers = mean ± Standard Error (S.E). Different litters = Significant Differences (p<0.05).

C= Control group, drenched orally with distilled water for (28) days.

T1= Drenched orally with MTX (0.250 mg /kg B.W/day) for (28) days.

T2= Drenched orally with Morin (25mg/kg B.W/day) for (28) days.

T3= Drenched orally with MTX (0.250 mg/kg/B.W)for (14) days then with Morin (25 mg/kg/B.W) for (14) days.

T4= Drenched orally with Morin (25 mg/kg/B.W) for (14) days then with MTX (0.250 mg/kg/B.W)for (14) days. T5= Drenched orally with MTX and Morin at the same time and simultaneously for (28) days.

IκB-α protein phosphorylation which works to keep NF-κB isolated and inactive in the cytoplasm (Karin, 1999). This was supported by the study of Imam *et al.* (2017) that the effect of routine (flavonide) in male white rats prevented the activation of NF-κB by increasing the expression of IκB-α, Abu Hashish *et al.* (2013) indicated

that the Maureen concentration of 30 mg/kg reduced the elevation of pro-inflammatory cytokines (IL-1β, IL-6, TNF-α) in rats. The role of Morin in inhibiting these factors is in the case of cancer in our experiment, however, we did not notice the effect of the negative control group as treated rats are intact.

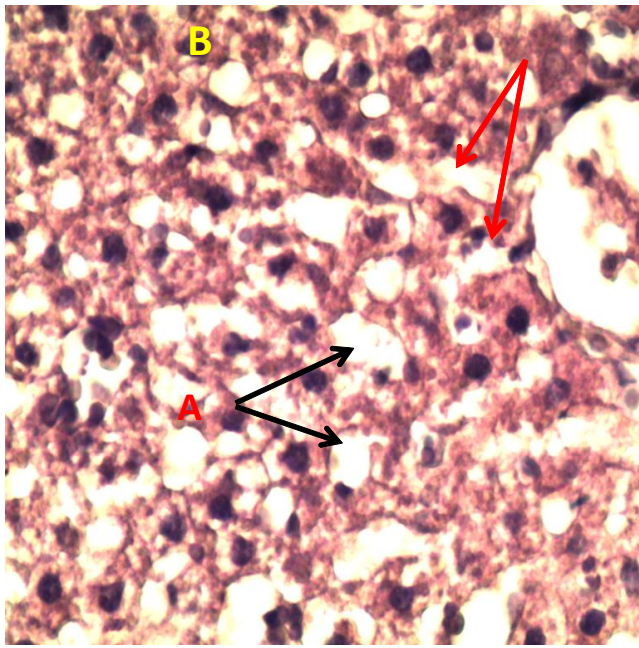


Fig. 1 : Cross section in the liver of a rat. Dosage of MTX (0.250 mg / kg for 28 days) shows A-Severe granular degeneration B-sinusoidal dilatation (40X H&E).

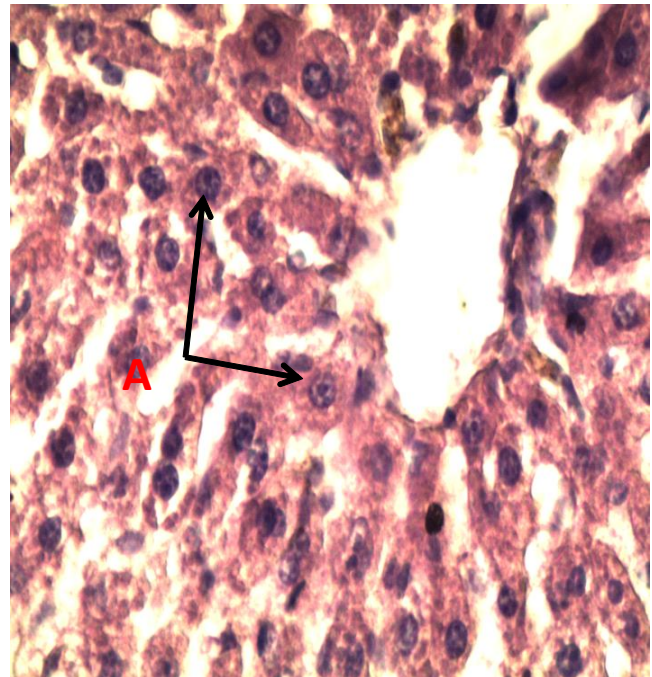


Fig. 2 : Liver section from rat treated with morin (25mg/kg/day for 28 days) showing normal morphology when compared with control rat (40X H&E).

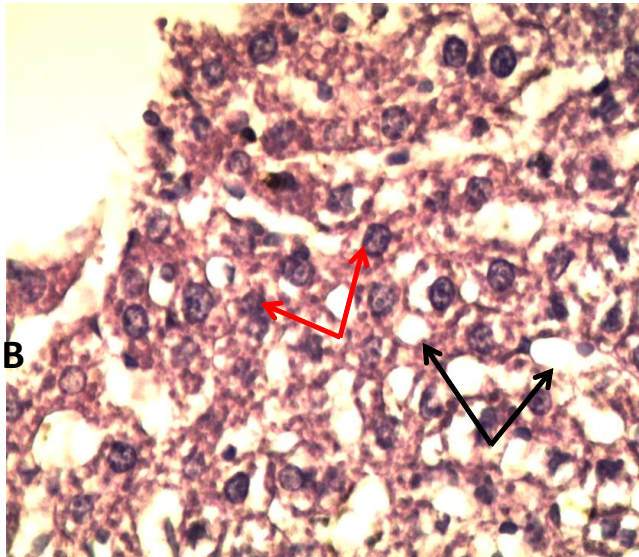


Fig. 3 : Cross section in the liver of a rat. MTX with Morin A- simple granular degeneration B- simple propagation in Kupffer cells (40X H&E).

Histopathological study

The liver and spleen were selected for histological study because they are the most affected organs because of its function in metabolism toxins and drugs. Agreed with the study of Tawfeeq and Taifoor (2014) of satisfactory histological changes in mice livers treated with MTX, as well as with the study of Al-Lami *et al.* (2017). Oxidative stress results in the accumulation of free radicals that cause damage to liver cells and tissue

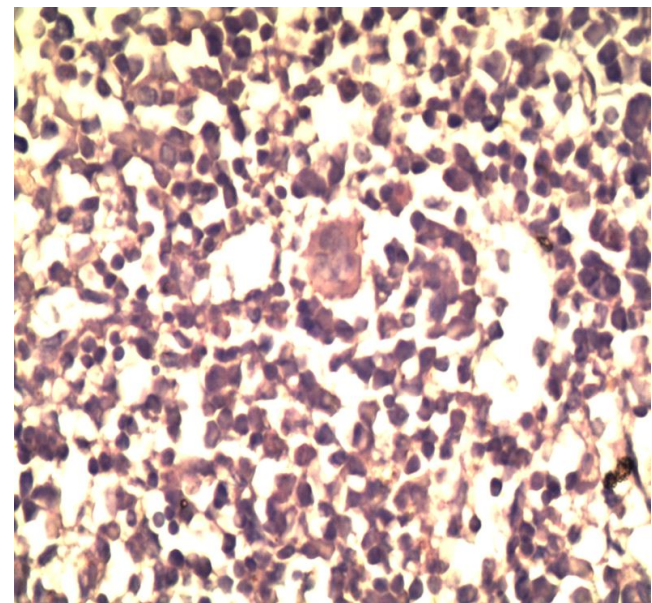


Fig. 4 : Cross section in the spleen of a rat. Dosage of MTX (0.250 mg / kg for 28 days) shows A-presence Multinucleated gaintcells B- lymphocyte degeneration in the white pulp(40X H&E).

damage (Majumdar *et al.*, 2008). Treatment with MTX also causes necrosis in hepatic cells due to accumulation of forms polyglutamate (It is a derivatives of MTX characterized by toxicity), which reduces folate levels in these cells, which may cause hepatic cells necrosis (Uraz *et al.*, 2008). On the other hand, in this study, the pathological changes were observed in the

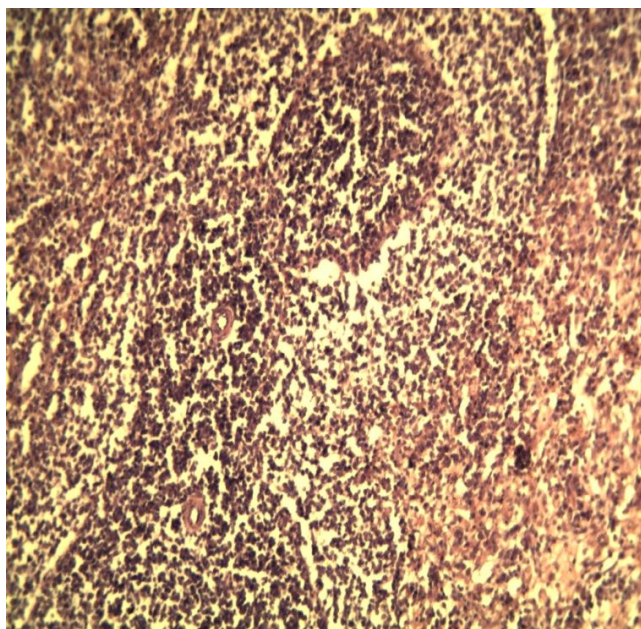


Fig. 5 : Cross section in the spleen of a rat treated with Morin (25mg/kg/ day for 28 days) A-white pulp B-arterioles C- thin trabeculae (10X H&E).

histopathological examination of MTX-treated rat spleen. These changes were consistent with Sakuhnol *et al.* (2013), when cisplatin was injected with rats. The white pulp deficiency and depletion is evident as a component of white blood cells that are reduced by the toxicity of MTX. As for the red pulp as a store of red blood cells that accumulate and hold inside the damaged pellets, which leads to increase and multiplication as a result of this accumulation, the spleen depletes its energy because of the extra effort to get rid of these pellets leading to some changes in spleen tissue (Klaassen *et al.*, 2009). Histological examination of the Morin-treated liver sections of the two groups (T3, T4) showed clear improvement, where Rizvi *et al.* (2015) pointed to the ability of Morin to protect hepatic cells from oxidative damage by enhancing cellular defenses such as regulating the activity of the nuclear factor 2 (Nrf2). Which has an effect on oxidative stress and toxicity so that it senses the oxidants and regulates the antioxidant defense (Ma, 2013). This improvement in liver tissue was evident in group (T5) and the ability of Morin to reduce fatty degeneration in the liver where the study of Gu *et al.* (2017) the Morin is a double antigen for liver liver X (LXR) with both quality α -, β -which is a nuclear receptor for transcription factors and is important in regulating cholesterol, fatty acids and glucose balance as well as affect the development of metabolic disorders such as hyperlipidemia and arteriosclerosis. They observed the treatment of mice with a high-fat diet that leads to obesity

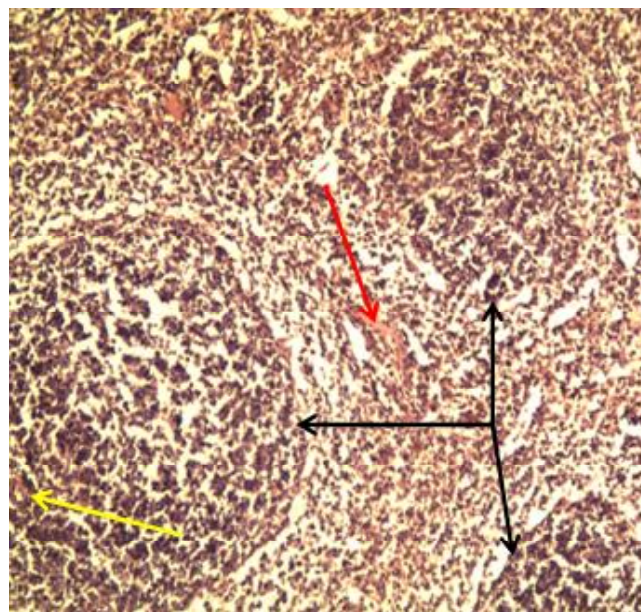


Fig. 6 : Cross section in the spleen of a rat. MTX with Morin :presence of a large white pulp and spread with the presence of arterioles surrounded by a red pulp and slight degeneration in lymphocytes (10X H&E).

with a dose of 100 mg of Morin led to delayed development of fatty liver (degeneration), lower body weight gains, lower levels of triglyceride and cholesterol level in serum and liver. Thus, Morin appears as a promising new treatment for fatty liver disease, Fang *et al.* (2005) reported that treatment with Maureen with the drug led to a significant improvement in spleen tissue in mice. Consistent with the study of both AL-Shanawi and Baker (2011) of the improvement of tissue for both liver and spleen when treated with antioxidants of flavonoids.

References

- Abbas, M. T. and M. M. H. Zayni (2012). Effect of Morin on Isoniazid and Rifampicin Induced Hepatotoxicity in Rats. *Kerbala Journal of Pharmaceutical Sciences*, **4** : 32-39.
- Abuhashish, H. M., S. S. Al-Rejaie, K. A. Al-Hosaini, M. Y. Parmar and M. M. Ahmed (2013). Alleviating effects of morin against experimentally-induced diabetic osteopenia. *Diabetology and Metabolic Syndrome*, **5(1)** : 5.
- Al-Fatlawi, A. A. Y. and M. M. M. Al-Shammari (2017). Rice bran phytic acid protects against methotrexate-induced oxidative stress and acute liver injury in rats. *Kufa Journal For Veterinary Medical Sciences*, **8(1)** : 249-260.
- Al-Lami, M. Q., A. I. Sail, S. M. Al-Chalab and F. A. Al-Mahdawi (2017). Study the Effects of Methotrexate with and without Vitamin A on Some Biochemical and Histological Parameters in Male Rabbits. *Journal of Biotechnology Research Center*, **11(1)** : 45-53.
- Al-Malaak, M. K. (2014). Histopathological changes on

- Splenomegaly induced in Experimental rats Wistar albino. *AL-Qadisiya Medical Journal*, **10(18)** : 50-62.
- AL-Shanawi, F. A. and N. N. Baker (2011). Study the effect of the mixture alcoholic extract of Peganumharmala seeds and cones of Cupressus sempervirens and their effect on viability of protoscolices of *Echinococcus granulosus in vivo*. *Journal of Biotechnology Research Center (Special number)*, **5(2)** : 44-52.
- Bachewal, P., C. Gundu, V. G. Yerra, A. K. Kalvala, A. Areti and A. Kumar (2017). Morin exerts neuroprotection via attenuation of ROS induced oxidative damage and neuroinflammation in experimental diabetic neuropathy. *BioFactors*, **44(2)** : 109-122.
- Balk, R. A. (2011). Methotrexate-induced lung injury. Up to Date Marketing professional. 19.1(ecappo6 vtd.com-84/137200.56FFC7D9C76-14.
- Baumann, H., K. R. Prowse, S. Marinkoviæ, K. A. Won and G. P. Jahreis (1989). Stimulation of hepatic acute phase response by cytokines and glucocorticoids. *Annals of the New York Academy of Sciences*, **557(1)** : 280-296.
- Berryman, A. M., A. C. Maritim, R. A. Sanders and J. B. Watkins (2005). Influence of treatment of diabetic rats with combinations of pycnogenol, β -carotene and α -lipoic acid on parameters of oxidative stress. *Journal of Biochemical and Molecular Toxicology*, **18(6)** : 345-352.
- Bonnefoi, M., M. Hasim, P. Sauvagnac, V. Burgat and J. P. Braun (1989). Liver enzyme changes in a guinea-pig model of facial eczema (*Sporidesmio toxicosis*). *Enzyme*, **42** : 39-46.
- Caselli, A., P. Cirri, A. Santi and P. Paoli (2016). Morin: a promising natural drug. *Current medicinal chemistry*, **23(8)** : 774-791.
- Chiad, I. A., H. S. Yossef, M. A. Al-Saidi and M. A. Abbas (2015). Evaluation of Some Immunological Markers in the Rheumatoid Arthritis Patients. *Iraqi Journal of Science*, **56(3C)** : 2488-2493.
- Cronstein, B. N., D. Naime and E. Ostad (1993). The anti-inflammatory mechanism of methotrexate. Increased adenosine release at inflamed sites diminishes leukocyte accumulation in an *in vivo* model of inflammation. *The Journal of Clinical Investigation*, **92(6)** : 2675-2682.
- Darwish, S. F., W. M. El-Bakly, H. M. Arafa and E. El-Demerdash (2013). Targeting TNF- α and NF- κ B activation by bee venom : role in suppressing adjuvant induced arthritis and methotrexate hepatotoxicity in rats. *PLoS One*, **8(11)** : e79284.
- Durak, I., O. Canbolat, M. Kavutçu, H. S. Öztürk and Z. Yurtarslani (1996). Activities of total, cytoplasmic and mitochondrial superoxide dismutase enzymes in sera and pleural fluids from patients with lung cancer. *Journal of Clinical Laboratory Analysis*, **10(1)** : 17-20.
- Fang, S. H., Y. C. Hou and P. D. L. Chao (2005). Pharmacokinetic and pharmacodynamic interactions of morin and cyclosporin. *Toxicology and Applied Pharmacology*, **205(1)** : 65-70.
- Fitzakerley, J. (2011). Antineoplastic. A-Folic acid analogues: Methotrexate, Pemertexed. Prevent DNA/ Antimetabolites Folic acid analogues/ Mechanism. Univ. of Minuesota Medical school. Duluth/Las modified 3- mar 11 4:28 PM.
- Galvez, J., G. Coelho, M. E. Crespo, T. Cruz, M. E. Rodríguez Cabezas, A. Concha and A. Zarzuelo (2001). Intestinal anti inflammatory activity of morin on chronic experimental colitis in the rat. *Alimentary Pharmacology & Therapeutics*, **15(12)** : 2027-2039.
- Gerards, A. H., S. de Lathouder, E. R. De Groot, B. A. C. Dijkmans and L. A. Aarden (2003). Inhibition of cytokine production by methotrexate. Studies in healthy volunteers and patients with rheumatoid arthritis. *Rheumatology*, **42(10)** : 1189-1196.
- Guidet, B. and S. V. Shah (1989). Enhanced *in vivo* H₂O₂ generation by rat kidney in glycerol-induced renal failure. *American Journal of Physiology-Renal Physiology*, **257(3)** : 440-445.
- Gu, M., Y. Zhang, C. Liu, D. Wang, L. Feng, S. Fan, B. Yang, Q. Tong, G. Ji and C. Huang (2017). Morin, a novel LXR α / β dual antagonist, has potent therapeutic efficacy for nonalcoholic fatty liver diseases. *British Journal of Pharmacology*, **174(18)** : 3032-3044.
- Heeba, G. H. and M. E. Mahmoud (2014). Therapeutic potential of morin against liver fibrosis in rats : modulation of oxidative stress, cytokine production and nuclear factor kappa B. *Environmental Toxicology and Pharmacology*, **37(2)** : 662-671.
- Hodek, P., P. Trefil and M. Stiborová (2002). Flavonoids-potent and versatile biologically active compounds interacting with cytochromes P450. *Chemico-Biological Interactions*, **139(1)** : 1-21.
- Hudson, N. M. C. (1999). Rethinking cystic fibrosis pathology glutathione system dysfunction and glutathione augmentation theory. *J. Pedia.*, **19** : 129.
- Imam, F., N. O. Al-Harbi, M. M. Al-Harbia, H. M. Korashy, M. A. Ansari, M. N. Sayed-Ahmed, M. Iqbal, K. Anwer, I. Kazmi and M. Afzal (2017). Rutin attenuates carfilzomib-induced cardiotoxicity through inhibition of NF- κ B, hypertrophic gene expression and oxidative stress. *Cardiovascular Toxicology*, **17(1)** : 58-66.
- Jahovic, N., H. Çevik, A. O. Žehirli, B. C. Yeđen and G. Ener (2003). Melatonin prevents methotrexate induced hepatorenal oxidative injury in rats. *Journal of pineal research*, **34(4)** : 282-287.
- Joda, M. (2008). The progressive statistical analysis by using SPSS. 1st ed. Walse House editions, Amman Jordan.
- Jwied, A. H. (2009). Hepatoprotective effect of the aqueous extract of camellia sinensis against methotrexate-induced liver damage in rats. *Iraqi Journal of Pharmaceutical Sciences*, **18(2)** : 73-79.
- Karin, M. (1999). How NF- κ B is activated: the role of the I κ B kinase (IKK) complex. *Oncogene*, **18(49)** : 6867-6874.
- Klaassen, C. D., J. Liu and B. A. Diwan (2009). Metallothionein protection of cadmium toxicity. *Toxicology and Applied Pharmacology*, **238(3)** : 215-220.
- Kok, L. D. S., Y. P. Wong, T. W. Wu, H. C. Chan, T. T. Kwok and

- K. P. Fung (2000). Morin hydrate: a potential antioxidant in minimizing the free-radicals-mediated damage to cardiovascular cells by anti-tumor drugs. *Life Sciences*, **67(1)**: 91-99.
- Lee, K. M., Y. Lee, H. J. Chun, A. H. Kim, J. Y. Kim, J. Y. Lee and J. Lee (2016). Neuroprotective and anti-inflammatory effects of morin in a murine model of Parkinson's disease. *Journal of Neuroscience Research*, **94(10)**: 865-878.
- Majumdar, A., M. Saraf, N. Andrades and R. Kamble (2008). Preliminary studies on the antioxidant activity of Tribulusterrestris and *Eclipta alba*. *Pharmacognosy Magazine*, **4(13)**: 102-107.
- Manna, S. K., R. S. Aggarwal, G. Sethi, B. B. Aggarwal and G. T. Ramesh (2007). Morin (3, 5, 7, 22, 42-Pentahydroxyflavone) Abolishes Nuclear Factor- κ B Activation Induced by Various Carcinogens and Inflammatory Stimuli, Leading to Suppression of Nuclear Factor- κ B-Regulated Gene Expression and Up-regulation of Apoptosis. *Clinical Cancer Research*, **13(7)**: 2290-2297.
- Ma, Q. (2013). Role of nrf2 in oxidative stress and toxicity. *Annual review of Pharmacology and Toxicology*, **53**: 401-426.
- Nair, K. G., K. V. Deepadevi, P. Arun, V. M. Kumar, A. Santhosh, L. R. Lekshmi and P. A. Kurup (1998). Toxic effect of systemic administration of low doses of the plasticizer di-(2-ethyl hexyl) phthalate [DEHP] in rats. *Indian Journal of Experimental Biology*, **36(3)**: 264-272.
- Ohbayashi, M., M. Suzuki, Y. Yashiro, S. Fukuwaka, M. Yasuda, N. Kohyama, Y. Kobayashi and T. Yamamoto (2010). Induction of pulmonary fibrosis by methotrexate treatment in mice lung *in vivo* and *in vitro*. *The Journal of Toxicological Sciences*, **35(5)**: 653-661.
- Parrish, C. R., RD, MS, Series Editor (2006). Serum Proteins as Markers of Nutrition: What Are We Treating. *Nutrition Issues in Gastroenterology*, **43**: 46-64.
- Patel, N. N., D. J. Ghodasara, S. Pandey, P. D. Ghodasara, J. H. Khorajiya, B. P. Joshi and C. J. Dave (2014). Subacute toxicopathological studies of methotrexate in Wistar rats. *Veterinary World*, **7(7)**: 489-495.
- Rabovsky, A. B., A. M. Komarov, J. S. Ivie and G. R. Buettner (2010). Minimization of free radical damage by metal catalysis of multivitamin/multi mineral supplements. *Nutrition Journal*, **9**: 61.
- Rawat, A. K. S., S. Mehrotra, S. C. Tripathi and U. Shome (1997). Hepatoprotective activity of Boerhaaviadiffusa L. roots—a popular Indian ethnomedicine. *Journal of Ethnopharmacology*, **56(1)**: 61-66.
- Rizvi, F., A. Mathur, S. Krishna, M. I. Siddiqi and P. Kakkar (2015). Suppression in PHLPP2 induction by morin promotes Nrf2-regulated cellular defenses against oxidative injury to primary rat hepatocytes. *Redox biology*, **6**: 587-598.
- Robinson, S. M., J. Scott, Manas DM SA White (2013). The assessment and management of chemotherapy associated liver injury. hepatic surgery, Prof. HeshamAbdeldayem (ed) ISBN: 978-953-51-0965-5.
- Rouse, K., E. Nwokedi, J. E. Woodliff, J. Epstein and V. S. Klimberg (1995). Glutamine enhances selectivity of chemotherapy through changes in glutathione metabolism. *Annals of Surgery*, **221(4)**: 420-426.
- Sail, A. I., F. A. Al-Mahdawi, M. Q. Al-Lami and S. M. Al-Jalabi (2013). Protective Effect of Vitamin A against Oxidative Stress Caused by Methotrexate. *Iraqi Journal of Science*, **54(3)**: 585-589.
- Sakhno, L. A., O. V. Yurchenko, V. N. Maslenniy, K. I. Bardakhivskaya, V. V. Nikolaeva, A. A. Ivanyuk, O. O. Shevchuk, V. G. Korotich and V. G. Nikolaev (2013). Enterosorption as a method to decrease the systemic toxicity of cisplatin. *ExpOncol*, **35**: 45-52.
- Sedlak, J. and R. H. Lindsay (1968). Estimation of total, protein-bound, and nonprotein sulfhydryl groups in tissue with Ellman's reagent. *Analytical Biochemistry*, **25**: 192-205.
- Singh, M. P., R. Jakhar and S. C. Kang (2015). Morin hydrate attenuates the acrylamide-induced imbalance in antioxidant enzymes in a murine model. *International Journal of Molecular Medicine*, **36(4)**: 992-1000.
- Sivaramakrishnan, V. and S. N. Devaraj (2010). Morin fosters apoptosis in experimental hepatocellular carcinogenesis model. *Chemico-biological Interactions*, **183(2)**: 284-292.
- Sneider, W. (2005). *Drug discovery : a history*. John Wiley & Sons.
- Sreedharan, V., K. K. Venkatachalam and N. Namasivayam (2009). Effect of morin on tissue lipid peroxidation and antioxidant status in 1, 2-dimethylhydrazine induced experimental colon carcinogenesis. *Investigational new Drugs*, **27(1)**: 21.
- Subash, S. and P. Subramanian (2012). Chronotherapeutic effect of morin in experimental chronic hyperammonemic rats. *International Journal of Nutrition, Pharmacology, Neurological Diseases*, **2(3)**: 266-271.
- Tawfeeq, A. A. and S. M. Taifoor (2014). Histopathological effects of Methotrexate in mice livers. *Kirkuk Uni J-Sci Studies*, **9(1)**: 18-27.
- Tousson, E., Z. T. Zaki, W. A. Abu-Shaer and H. Hassan (2014). Methotrexate-induced hepatic and renal toxicity: role of L-carnitine in treatment. *Biomed Biotechnol.*, **2(4)**: 85-92.
- Yao, D., H. Cui, S. Zhou and L. Guo (2017). Morin inhibited lung cancer cells viability, growth and migration by suppressing miR-135b and inducing its target CCNG2. *Tumor Biology*, **39(10)**: 1-9.
- Weiji, N., T. J. Elseendoorm and E. G. Lentjes (2004). Supplementation with antioxidant micronutrients and cancer patients treated with cisplatin based chemotherapy: A randomized double blind placebo-controlled study. *E. Ur. J. Cancer*, **40(11)**: 1713-1723.
- Zheng, X. N., X. W. Wang, L. Y. Li, Z. W. Xu, H. Y. Huang, J. S. Zhao, D. Zhang, X. Yin, J. Sheng and J. T. Tang (2014). Puerh tea powder preventive effects on cisplatin-induced liver oxidative damage in Wistar rats. *Asian Pac. J. Cancer Prev.*, **15(17)**: 7389-7394.